Rectal Tube Placement in Multiparametric MRI of the Prostate: Multi-Reader Evaluation of Image Quality Improvement

Yu-Hui Huang, MD, MS; Can Ozutemiz, MD; Nathan Rubin, MS; Robben Schat, DO; Gregory J Metzger, PhD
Benjamin Spilseth, MD, MBA

Introduction

Multiparametric magnetic resonance imaging of the prostate has become increasingly important in the diagnosis and treatment planning of prostate cancer. DWI is an integral part of the mpMRI protocol recommended by PIRADS v2.1. However, DWI is prone to susceptibility-related artifacts that occur at the interface of air and soft tissue and degrade image quality. Several strategies have been proposed to reduce susceptibility-related and motion artifacts including antispasmodic agents and enemas. Placement of a rectal tube has been recommended to remove air from the rectum, and rectal tube placement was previously reported for a small number of exams performed using an endorectal coil. To our knowledge, the impact of routine rectal tube placement prior to prostate mpMRI has not yet been systematically investigated and published. Therefore, the aim of the current study is to determine the impact of rectal tube placement on image quality and artifact reduction of prostate mpMRI.

Methodology

This IRB-approved retrospective study included 196 consecutive patients that consisted of 97 patients who underwent 3T mpMRI of the prostate with a rectal tube and 99 without. All MRI acquisition parameters remained the same with the exception of rectal tube placement. Two radiologists rated images on several parameters with a 5-point Likert scale (from 1=none/excellent to 5=severe/poor). Inter-observer agreement was assessed using Cohen's Kappa. Image parameter scores were compared between groups using 2-sample t-tests. Statistical significance was defined as $p < 0.05$. All analyses were performed using R v3.6.

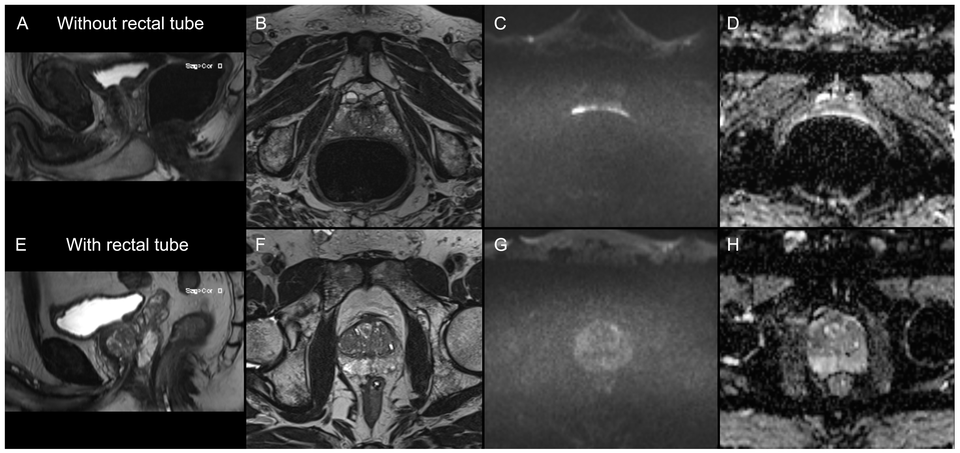

Fig. 1—Multiparametric MRI of the prostate without rectal tube versus with rectal tube. 70-year-old man who underwent prostate mpMRI without rectal tube demonstrates a large volume of rectal gas with a score of 5 (large rectal gas present) from both readers on T2WI sagittal (A) and axial (B) images, 5 (severe) DWI distortion (C) and 5 (poor) ADC map quality (D). 60-year-old man who underwent prostate mpMRI with the placement of rectal tube received a score of 1 (none/excellent) from both readers for all image parameters including presence of rectal gas on T2WI sagittal (E) and axial (F) images, DWI distortion (G) and ADC map quality (H).

Results

196 patients were included in the analysis, where 97 patients had a rectal tube placed prior to imaging and 99 without. There was substantial agreement for ADC map quality (κ = 0.80), almost perfect agreement for DWI distortion (κ = 0.84) and presence of rectal gas (κ = 0.85), and moderate agreement for T2WI motion artifacts (κ = 0.55). Inter-observer agreement for rectal diameter using Pearson correlation was high ($r = 0.90$, $p < 0.001$). None of the patients with rectal tube placement had a score of 5 for poor quality or severe artifacts, compared to 19 patients without a rectal tube. The overall quality of the ADC maps in the rectal tube group was significantly better than the no-tube group ($p < 0.001$). DWI distortion artifacts in the rectal tube group were significantly less than in the no-tube group ($p < 0.001$). T2WI motion artifact in the rectal tube group was significantly different than in the no-tube group ($p = 0.02$). Presence of rectal gas in the rectal tube group was significantly less than in the no-tube group ($p < 0.001$) with significantly smaller mean rectal diameter in the rectal tube group (17.7 ± 10.4 mm) than in the no-tube group (21.5 ± 11.4 mm; $p = 0.016$). The median tube depth of insertion was 8.7 cm with a range of 2.0 cm to 16.9 cm. A tube depth of greater than or equal to 8.7 cm was significantly associated with improved ADC quality (0.32 lower, $p = 0.037$), a lower (better) average DWI distortion score (0.41 lower, $p = 0.011$), and less rectal gas (0.50 lower, $p < 0.005$) as compared to those with a tube depth of lower than 8.7 cm (Fig S1-2). These trends held when treating tube depth continuously. T2 motion artifacts and rectal diameter were not significantly associated with tube depth.

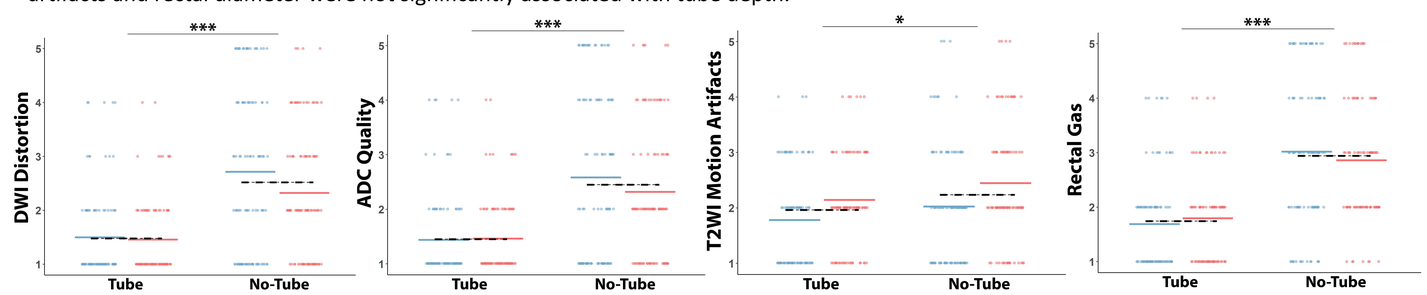

Fig. 2—Scores of image parameters. Scores on (A) DWI distortion artifacts ($p < 0.001$), (B) ADC map quality ($p < 0.001$), (C) T2WI motion artifacts ($p = 0.02$), and (D) presence of rectal gas ($p < 0.001$) between tube groups by reader 1 (blue) and reader 2 (red) with horizontal colored bar (mean for each reader) and black horizonal bar (mean for both readers).

Image Parameter	Rectal Tube	No-Tube	p-value	Kappa
DWI distortion, mean ± SD	1.5 ± 0.8	2.5 ± 1.3	< 0.001	0.84
ADC overall quality, mean ± SD	1.5 ± 0.8	2.4 ± 1.3	< 0.001	0.80
T2WI motion artifact, mean ± SD	2.0 ± 0.8	2.2 ± 1.0	0.020	0.55
Rectal gas, mean ± SD	1.8 ± 0.9	2.9 ± 1.2	< 0.001	0.85
Rectal diameter (mm), mean ± SD	17.7 ± 10.4	21.5 ± 11.4	0.016	0.90*

Table 1: Image parameter scores for rectal tube group and no-tube group.

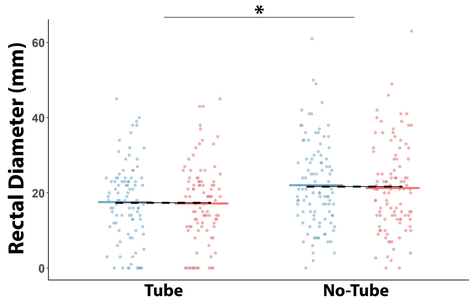

Fig. 2—Rectal diameter between tube groups ($p = 0.016$) by reader 1 (blue) and reader 2 (red) with horizontal colored bar (mean for each reader) and black horizonal bar (mean for both readers).

Conclusion

Rectal tube placement during prostate mpMRI significantly diminishes rectal gas, improves associated distortion artifacts on DWI, motion artifacts on T2WI, and overall quality of ADC maps. These results support the practice of rectal tube placement for routine patient preparation during prostate mpMRI as it provides significant benefit to the image quality.

MEDICAL SCHOOL
UNIVERSITY OF MINNESOTA
Department of Radiology